

Anterior Hip & Groin Pain

Contemporary Diagnostic & Management Strategies

Dr. Alison Grimaldi

PHYSIOTHERAPIST, RESEARCHER & EDUCATOR

Anterior Hip & Groin Pain
Contemporary diagnostic & management strategies


Dr Alison Grimaldi
BPhy, MPhy(Sports), PhD
Australian Sports Physiotherapist
Practice Principal Physiotherapist
Adjunct Senior Research Fellow
University of Queensland,
Australia

@alisongrimaldi www.dr.alisongrimaldi.com

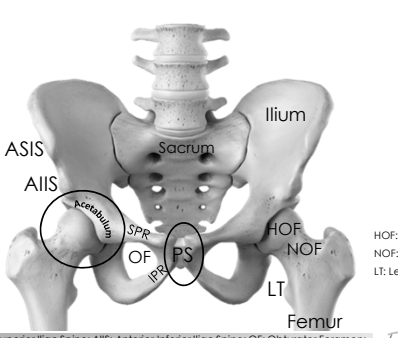


1

Anatomy of the anterior hip & groin



2

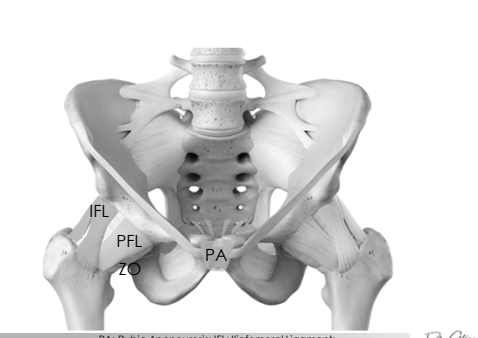


ASIS
AIIS
Acetabulum
SPR
OF
IPR
PS
Ilium
Sacrum
HOF
NOF
LT
Femur

HOF: Head of Femur
NOF: Neck of Femur
LT: Lesser Trochanter

ASIS: Anterior Superior Iliac Spine; AIIS: Anterior Inferior Iliac Spine; OF: Obturator Foramen;
SPR: Superior Pubic Ramus; IPR: Inferior Pubic Ramus; PS: Pubic Symphysis

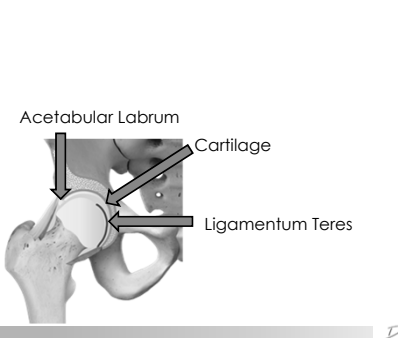
3



IFL
PFL
ZO
PA

PA: Pubic Aponeurosis; IFL: Iliofemoral Ligament;
PFL: Pubofemoral Ligament; ZO: Zona Orbicularis

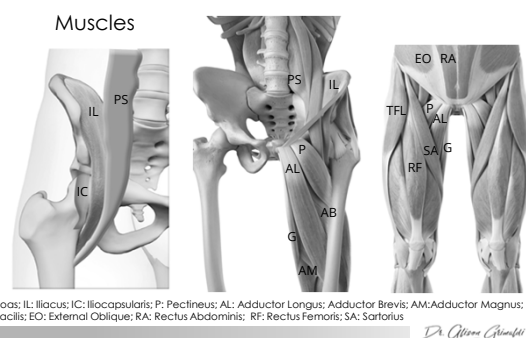
4



Acetabular Labrum
Cartilage
Ligamentum Teres

5

Muscles



PS: Psoas; IL: Iliacus; IC: Iliocapsularis; P: Pectineus; AL: Adductor Longus; Adductor Brevis; AM: Adductor Magnus;
G: Gracilis; EO: External Oblique; RA: Rectus Abdominis; RF: Rectus Femoris; SA: Sartorius

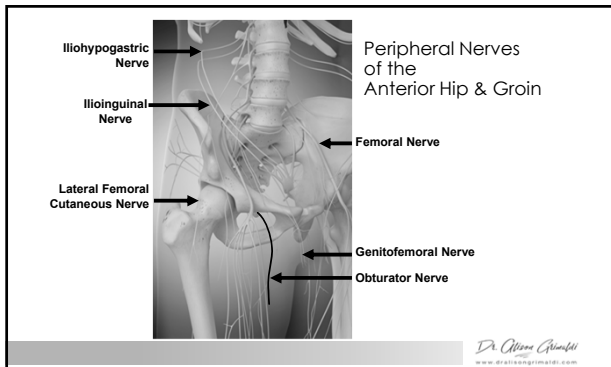
6

Anterior Hip & Groin Pain

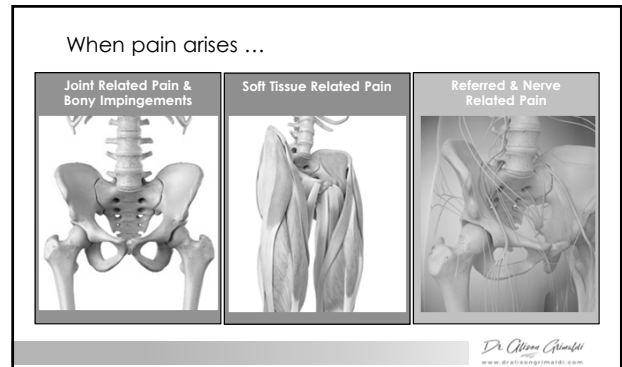
Contemporary Diagnostic & Management Strategies

Dr. Alison Grimaldi

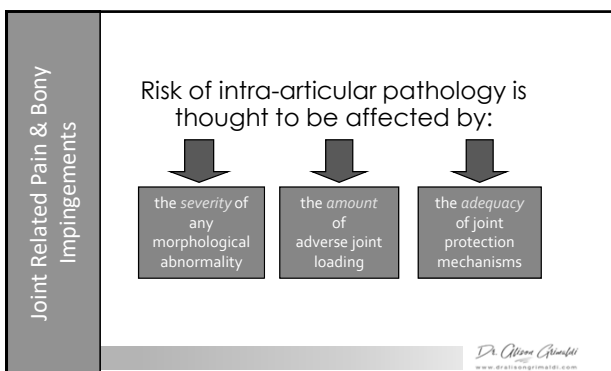
PHYSIOTHERAPIST, RESEARCHER & EDUCATOR



7



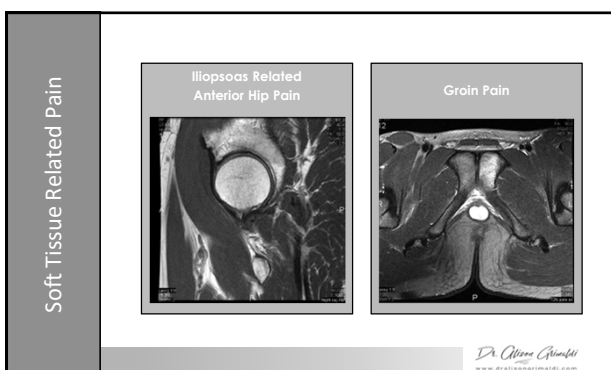
8



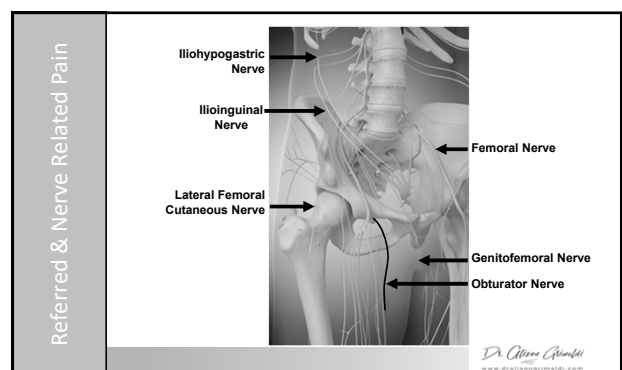
9

Key Morphological Variants		
Femoral Morphology	Acetabular Morphology	Capsulo-labral Deficiency
Cam Morphology (FAI)	Overcoverage (FAI)	Congenital Hypermobility
Coxa Valga/Vara	Retroversion (FAI)	Acquired Trauma
Coxa Breva	Dysplasia Type I & II	Iatrogenic
Femoral Version		Focal overload
Retroversion		
Anteversión		

10



11



12